

Treatment of Ectopic Maxillary Canines Using a Palatal Implant for Anchorage

ALDO GIANCOTTI, DDS, MS
MARIO GRECO, DDS
GIANLUCA MAMPIERI, DDS
CLAUDIO ARCURI, MD, DDS

Various types of palatal implants have been proposed for use as skeletal anchorage in orthodontic treatment.¹⁻⁵ In 1992, Wehrbein and colleagues, in collaboration with the Straumann Institute, introduced the Orthosystem*—a sandblasted, chemically treated mini-implant that is narrower (3.3mm), but longer (4mm or 6mm), than previous types.⁶⁻⁹ More recently, Giancotti and colleagues showed a step-by-step procedure for insertion of the Straumann Orthosystem in the midpalatal area,¹⁰ along with its application as skeletal anchorage in extraction treatment.^{11,12}

This article describes a new Implant-Supported Deimpactor System (ISDS), in which an Orthosystem palatal implant is used for anchorage in the treatment of impacted maxillary canines.

Implant Design and Placement

The Straumann Orthosystem palatal mini-implant consists of a pure titanium (grade 4) intraosseous screw with a smooth, transmucosal neck (2.5mm or 4.5mm long) and an exposed, 2mm head, to which a healing cap is attached (Fig. 1). The self-tapping threads are sandblasted and acid-etched for optimal primary stability.

*Institut Straumann AG, Basel, Switzerland; distributed by Straumann USA, LLC, 60 Minuteman Road, Andover, MA 01810.

Placement of the screw is based on three parameters as assessed on the lateral cephalogram:

1. The position of the implant in the palate.
2. The angle between the implant axis and the palatal plane.
3. The distance between the most cranial border of the implant and the most cranial border of the palatal complex.

Under local anesthesia, the palatal mucosa is removed with a mucosal trephine (4.2mm in diameter). Pilot drilling of the implant site is then performed with a standard round bur and profile drill.



Fig. 1 Straumann Orthosystem palatal implant (4mm long, with 2.5mm transmucosal neck).

Dr. Giancotti is an Assistant Professor and Drs. Greco and Mampieri are former residents, Department of Orthodontics, and Dr. Arcuri is an Associate Professor of Periodontology, Department of Oral Surgery, Fatebenefratelli Association for Research, Fatebenefratelli Hospital, University of Rome "Tor Vergata", Rome, Italy. Contact Dr. Giancotti at Viale Gorizia 24/c, 00198 Rome, Italy; e-mail: giancotti@uniroma2.it.



Dr. Giancotti



Dr. Greco



Dr. Mampieri



Dr. Arcuri

After 10 weeks, the healing cap is replaced by an impression cap, and a precise impression of the upper arch is taken in polyvinyl siloxane. The impression cap allows the laboratory to reproduce the exact position of the implant in the plaster cast, so that the orthodontic force system can be properly constructed.

The active portion of the ISDS is made in one of two designs:

Type 1 (Fig. 2A). Two lingual sheaths with rectangular openings are soldered to a steel cap, which is attached to the palatal implant. An .032" TMA** spring is inserted in each lingual sheath for maxillary molar distalization.¹³ Two .040" stainless steel arms are soldered to the mesial portion of the steel cap for initial extrusion of the impacted teeth.

Type 2 (Fig. 2B). The .032" TMA springs are inserted in the lingual sheaths as cantilever arms to produce extrusion of the impacted teeth in the vertical plane. Further labial movement of the impacted canines is performed with the cantilever arms activated in the horizontal plane.

Case Report

A 22-year-old female presented with a Class I malocclusion (Fig. 3). Her maxillary deciduous canines were still present, and the maxillary permanent canines were impacted in the palatal bone. Because the maxillary molars were mesially rotated, there was insufficient space for eruption of the permanent canines. Mild crowding was evident in the mandibular arch.

The treatment plan was to correct the molar relationship by maxillary molar distalization, guide the permanent canines into their normal positions, and finish the occlusion with a phase of fixed appliance treatment.

A Straumann Orthosystem palatal implant was surgically inserted as described above.¹¹⁻¹³ After healing, an ISDS Type 1 was used to simultaneously correct the molar positions and extrude the impacted canines (Fig. 4). The distalizing springs were activated at an angle of 45° to the

**Registered trademark of Ormco/"A" Company, 1717 W. Collins Ave., Orange, CA 92867.

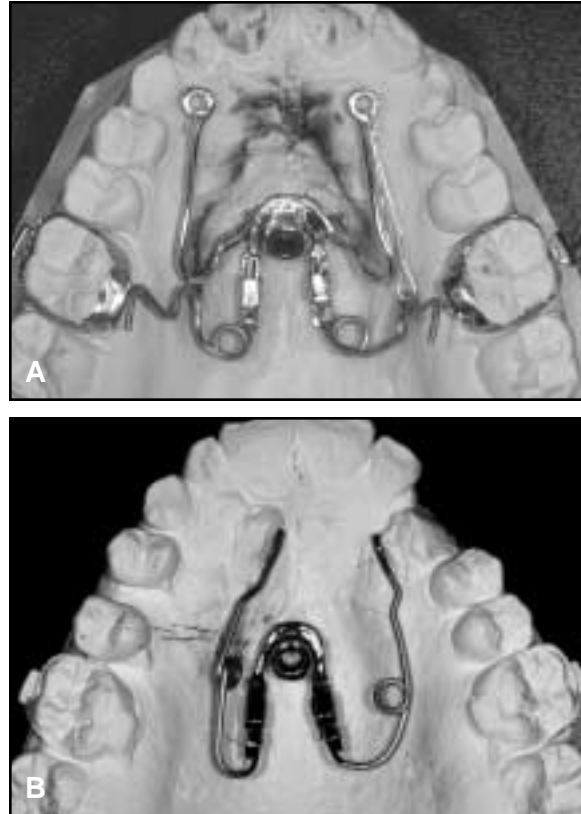


Fig. 2 Implant-Supported Deimpactor System (ISDS). A. Type 1. B. Type 2.

palatal plane, exerting a force of about 150g per side. Three months later, the impacted canines were surgically exposed and lightly tied to the stainless steel arms of the appliance with elastic thread. After another three months, the left canine, which had been in a more favorable position, was close to its correct location in the arch, while the right canine, which had been more deeply impacted, was somewhat extruded (Fig. 5).

An ISDS Type 2 was then used to complete the canine correction (Fig. 6). The .032" TMA cantilever springs were inserted into the lingual sheaths and activated in both the occlusal and buccal planes. Four months later, both canines had reached their proper positions in the maxillary arch (Fig. 7).

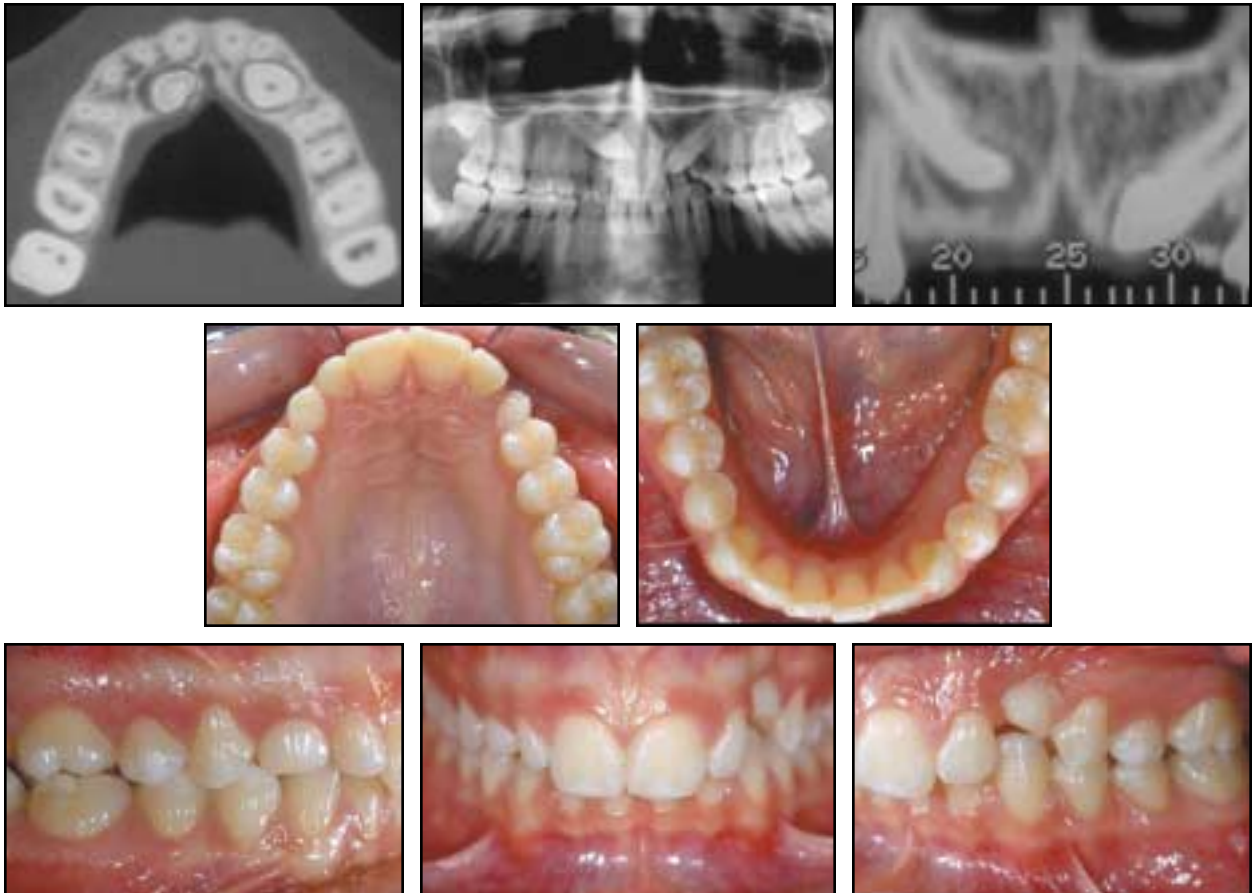

Fig. 3 22-year-old female patient with retained maxillary deciduous canines and impacted maxillary permanent canines before treatment.

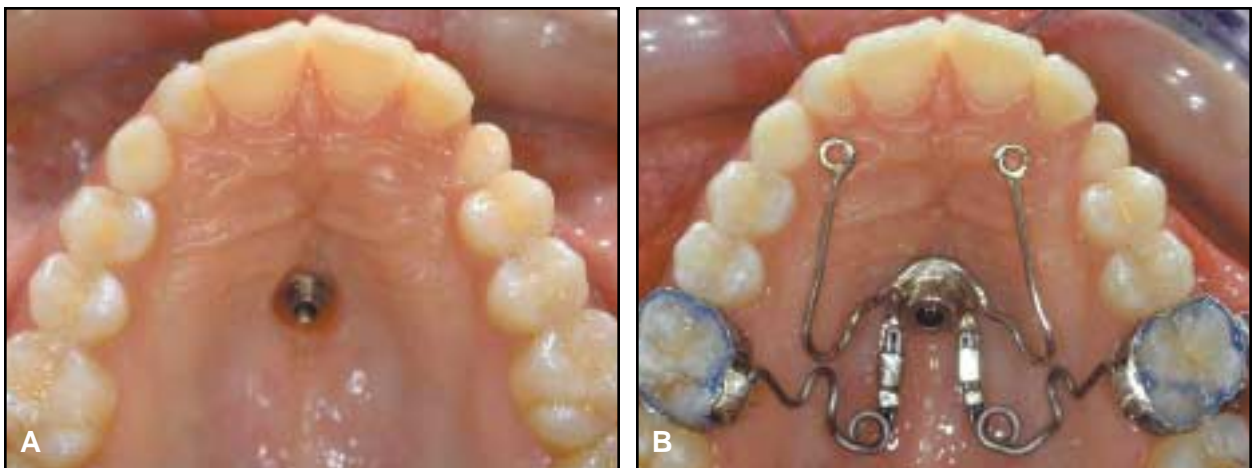


Fig. 4 A. Insertion of Straumann Orthosystem palatal implant. B. Placement and activation of ISDS Type 1.

Treatment of Ectopic Maxillary Canines Using a Palatal Implant for Anchorage

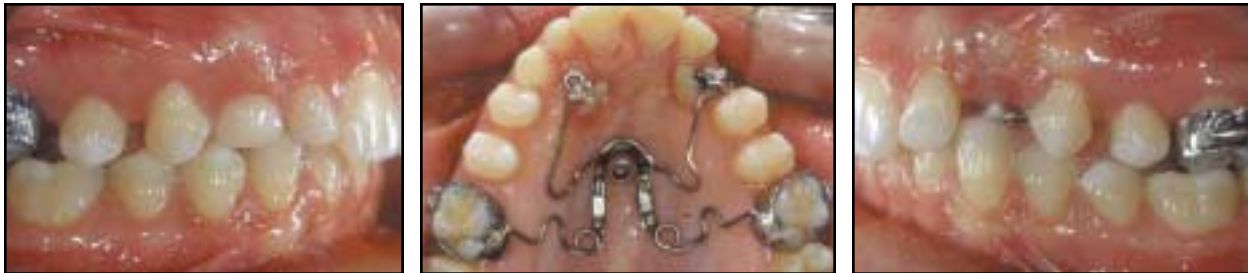

Fig. 5 Distalization of maxillary molars and extrusion of impacted canines after five months of treatment.

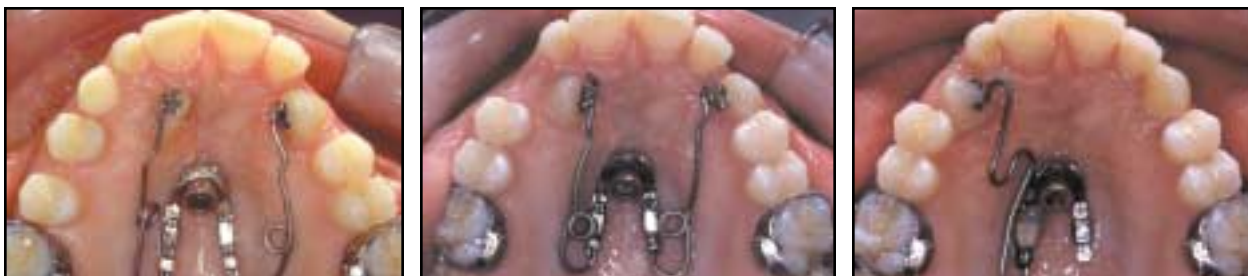

Fig. 6 Progress of impacted canines during four months of treatment with ISDS Type 2.

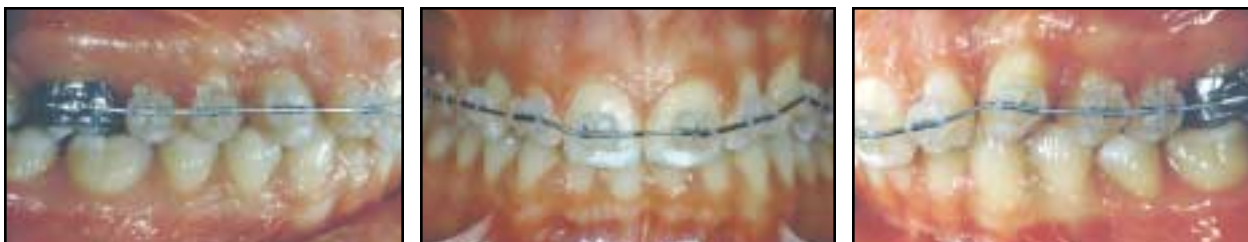

Fig. 7 Finishing phase using fixed appliance.

The finishing phase, including root torque correction, was performed with about six months of fixed appliance wear. At the end of treatment, crown veneers were recommended for esthetic improvement of the upper lateral incisors (Fig. 8).

Discussion

In the treatment of impacted canines, stable anchorage is essential to maintain the transverse arch dimensions and minimize side effects. Vertical movement of the impacted teeth is usually achieved with cantilever springs, while horizontal movement is obtained by direct traction toward the archwire. When a cantilever spring is

inserted in the auxiliary slot of the molar band, however, its activation can produce undesirable molar tipping. Therefore, a transpalatal bar or other palatal anchorage device is usually needed to prevent side effects on the anchor teeth.

The use of a palatal implant for skeletal anchorage offers three main advantages:

1. Osseointegration ensures the stability of the implant after orthodontic loading, so that all the reactive forces are borne by the implant, rather than by any dental structures.
2. The active arms can be directly soldered to the steel cap to exert either vertical or horizontal forces without loss of anchorage. The TMA springs, in contrast to stainless steel cantilever springs, exert a gradual and effective force and

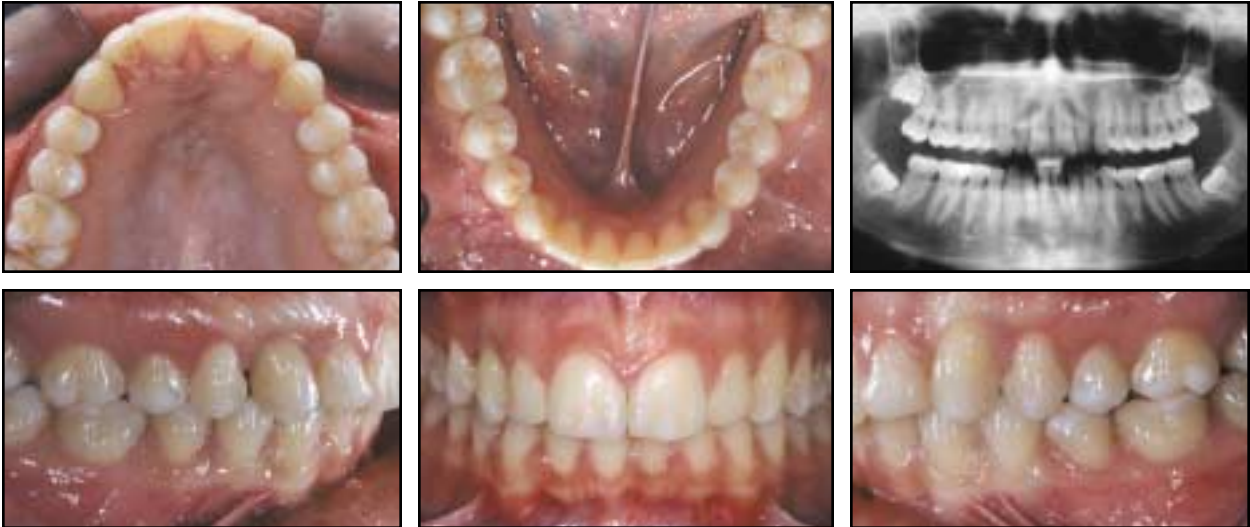

Fig. 8 Patient after 16 months of treatment.

can be easily reactivated if necessary.

3. No special cooperation is required from the patient. This is particularly useful in the treatment of impacted canines, which is often lengthy.

The surgical procedure plays an important role in the long-term periodontal health of deeply impacted maxillary canines. The window technique of surgical exposure has been associated with a significant loss of attachment, recession, and gingival inflammation.¹⁴ To avoid these effects, either a part of the keratinized gingiva must be preserved or an apically positioned flap should be raised. The surgical insertion and removal of the palatal implant is not complex, and is normally well tolerated by the patient.

ACKNOWLEDGMENTS: This article is dedicated to the memory of Dr. Aldo Carano. The authors wish to thank Orthosystem Laboratories of Rome and Mr. Stefano Della Vecchia for their technical support and for manufacturing the devices shown in this article.

REFERENCES

1. Triaca, A.; Antonini, M.; and Wintermantel, E.: Ein neues Titan-Flachschrauben-Implantat zur orthodontischen Verankerung am anterioren Gaumen, *Inf. Orthod. Kieferorthop.* 24:251-257, 1992.
2. Block, M.S. and Hoffman, D.R.: A new device for absolute anchorage for orthodontics, *Am. J. Orthod.* 107:251-258, 1995.
3. Bondemark, L.; Feldmann, I.; and Feldmann, H.: Distal molar movement with an intra-arch device provided with the Onplant

- System for absolute anchorage, *World J. Orthod.* 3:117-124, 2002.
4. Maino, B.G.; Mura, P.; and Gianelly, A.A.: A retrievable palatal implant for absolute anchorage in orthodontics, *World J. Orthod.* 3:125-134, 2002.
5. Karcher, H.; Byloff, F.K.; and Clar, E.: The Graz implant supported pendulum, a technical note, *J. Craniofac. Surg.* 30:87-90, 2002.
6. Wehrbein, H.; Feifel, H.; and Diedrich, P.: Palatal implant anchorage reinforcement of posterior teeth: A prospective study, *Am. J. Orthod.* 116:678-686, 1999.
7. Wehrbein, H.; Glatzmaier, J.; Mundwiler, U.; and Diedrich, P.: The Orthosystem: A new implant system for orthodontic anchorage in the palate, *J. Orofac. Orthop.* 57:142-153, 1996.
8. Wehrbein, H.; Merz, B.R.; and Diedrich, P.: Palatal bone support for orthodontic implant anchorage reinforcement: A clinical and radiological study, *Eur. J. Orthod.* 21:65-70, 1999.
9. Wehrbein, H.; Merz, B.R.; Diedrich, P.; and Glatzmaier, J.: The use of palatal implants for orthodontic anchorage: Design and clinical application of the Orthosystem, *Clin. Oral Implants Res.* 7:410-416, 1996.
10. Giancotti, A.; Muzzi, F.; Santini, F.; and Arcuri, C.: Straumann Orthosystem method for orthodontic anchorage: Step by step procedure, *World J. Orthod.* 3:140-146, 2002.
11. Giancotti, A.; Greco, M.; Docimo, R.; and Arcuri, C.: Extraction treatment using a palatal implant for anchorage, *Austral. Orthod. J.* 19:87-90, 2003.
12. Giancotti, A.; Greco, M.; Mampieri, G.; and Arcuri, C.: Clinical management in extraction cases using palatal implant for anchorage, *J. Orthod.* 31:288-294, 2004.
13. Giancotti, A.; Muzzi, F.; Greco, M.; and Arcuri, C.: Palatal implant-supported distalizing devices: Clinical application of the Straumann Orthosystem, *World J. Orthod.* 3:135-139, 2002.
14. Crescini, A.; Clauser, C.; Giorgetti, R.; Cortellini, P.; and Pini Prato, G.P.: Tunnel traction of infraosseous impacted canines. A three-year periodontal follow-up, *Am. J. Orthod.* 105:61-72, 1994.